CASE REPORT

Periductal Stromal Sarcoma of Breast: Case Report of a Rare Entity

Prachi Gupta*, Arpita Jindal, Aditi Jain***

ABSTRACT

Primary soft tissue sarcomas of the breast constitute less than 5% of all soft tissue sarcomas and less than 1% of malignant breast cancers.

Herein, we report a case of 50-yr-old female, who presented with right sided breast mass and was diagnosed as high grade periductal sarcoma of breast.

INTRODUCTION

Primary breast sarcoma is a rare entity and occurs in less than 1% of women with breast malignancy, first described in 1887[1]. Periductal stromal sarcoma (PSS) is an extremely rare neoplasm arising in the connective tissue of the breast, especially from the periductal stroma[2].

PSS is a distinct low grade breast sarcoma with no clinical or radiological specificity. It has a biphasic morphology with benign ductal elements and a sarcomatous stroma lacking phyllodes tumor architecture. In contrast to fibroadenomas and the phyllodes tumor, which appear to originate from the intralobular stroma, the distribution of the proliferation in PSS suggests an origin in the periductal or perilobular stroma. Similar to phyllodes tumors, PSS has a tendency for local recurrence when incompletely excised, and a potential to develop specific soft tissue sarcomas, as well as metastasis[3]. The therapeutic management of PSS is based on wide surgery with free margins, and adjuvant therapies are not required.

CASE REPORT

A 50-year-old woman, presented with a large right sided breast mass. HRCT thorax showed multiple large lobulated hypodense solid cystic masses in right breast. Fat planes with the pectoralis muscle were preserved and possibility of phylloides tumour was kept. Patient underwent a mastectomy.

Grossly the tumour comprised of 2 masses measuring 12x11x10cm and 9x8x5cm (Fig. 1).

External surface was smooth; cut surface was grey brown fleshy with areas of hemorrhage. Microscopic examination revealed spindle cells arranged in fascicles showing mild to moderate pleomorphism. Mitosis was brisk. Focal necrosis was seen. The epithelial element was difficult to find hence more tissue was processed whatever small ductal elements were seen, did not show any intracanalicular or leaf like pattern (Fig -2). Immunohistochemical analysis of the tumour cells showed diffuse positivity for vimentin, CD34 and CD10 (Fig-3) and were negative for pan CK, P63,CD117, Desmin and PR. Ki-67 index was 20%. A diagnosis of high grade periductal sarcoma was rendered.

DISCUSSION:

PSS was previously considered to be a variant of cystosarcoma with adipose metaplasia[4-6], however, currently, PSS was classified as a different entity by WHO in 2002 because of lack of phylloides architexture[7]. PSS occurs in pre and post menopausal women with a median of age of 55.3 years and the symptoms most commonly found are similar to other benign and malignant breast tumors and have no radiological specificity[8].

Histologically, PSS is a biphasic breast tumor with benign ductal elements and a sarcomatous stroma lacking phyllodes architecture. This tumor is characterized by a hypercellular proliferation of spindle cells forming cuffs around well-preserved ductal units with infiltration of the fat and surrounding tissue.

* Senior Demonstrator, **Senior Professor
Department of Pathology, SMS Medical College, Jaipur
Corresponding Author
Dr. Prachi Gupta
Senior Demonstrator, Pathology, SMS Medical College, Jaipur
E-mail: dr.prachigupta@gmail.com
Contact No. 8107572550

Adjacent cuffs may coalesce to form large nodules and extend into lobules surrounding open tubules and ducts. This is in contrast to mammary stromal sarcomas, which displace normal mammary tissue, entrapping ducts and lobules peripherally[9].

The histological features of PSS were defined by the Armed Forces Institute of Pathology[10] as follows: (a) a predominantly spindle-cell stromal proliferation of variable cellularity and atypia around open tubules and ducts devoid of a phyllodes pattern (b) one or, more often, multiple nodules separated by adipose tissue (c) stromal mitotic activity of ⩾3/10 high-power fields and (d) infiltration into surrounding mammary fibro adipose tissue.

PST is a tumor of intermediate behavior and resection with significant margin is considered sufficient for treatment. Adjuvant chemotherapy or radiotherapy is not recommended[10].

PSS may evolve into a phyllode tumor as well as a specific soft-tissue sarcoma. Also, PSS may occasionally exhibit intraepithelial changes ranging from ordinary hyperplasia to intra- ductal carcinoma[11]. The case is being reported for its rarity.

Figure 1: the tumor was grossly well circumscribed 12x11x10cm. cut surface –graybrown.

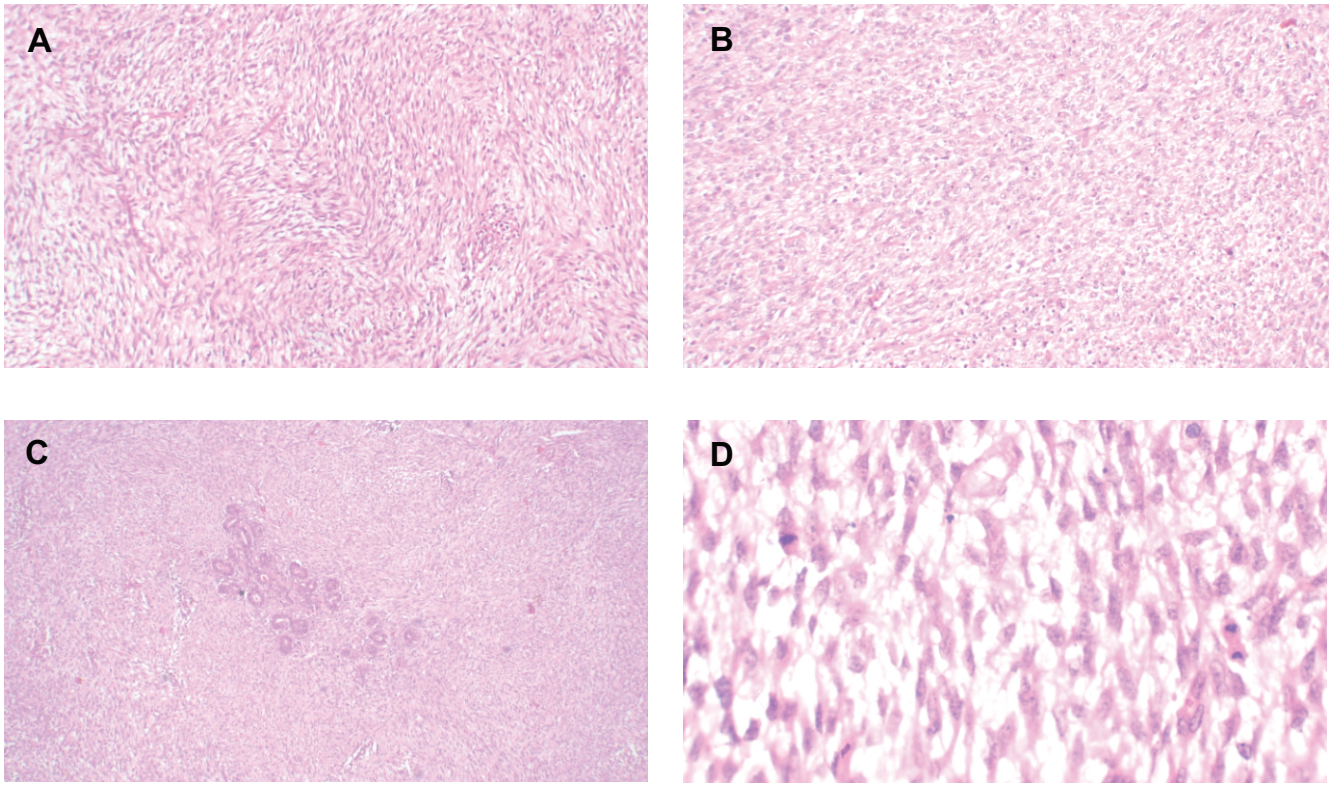

Figure 2:H and E Stain: A and B(low power)- spindle cells arranged in fascicles.
C (scanner view)-Preserved ductal elements.
D (High power)-stromal cells show moderate pleomorphism with mitosis

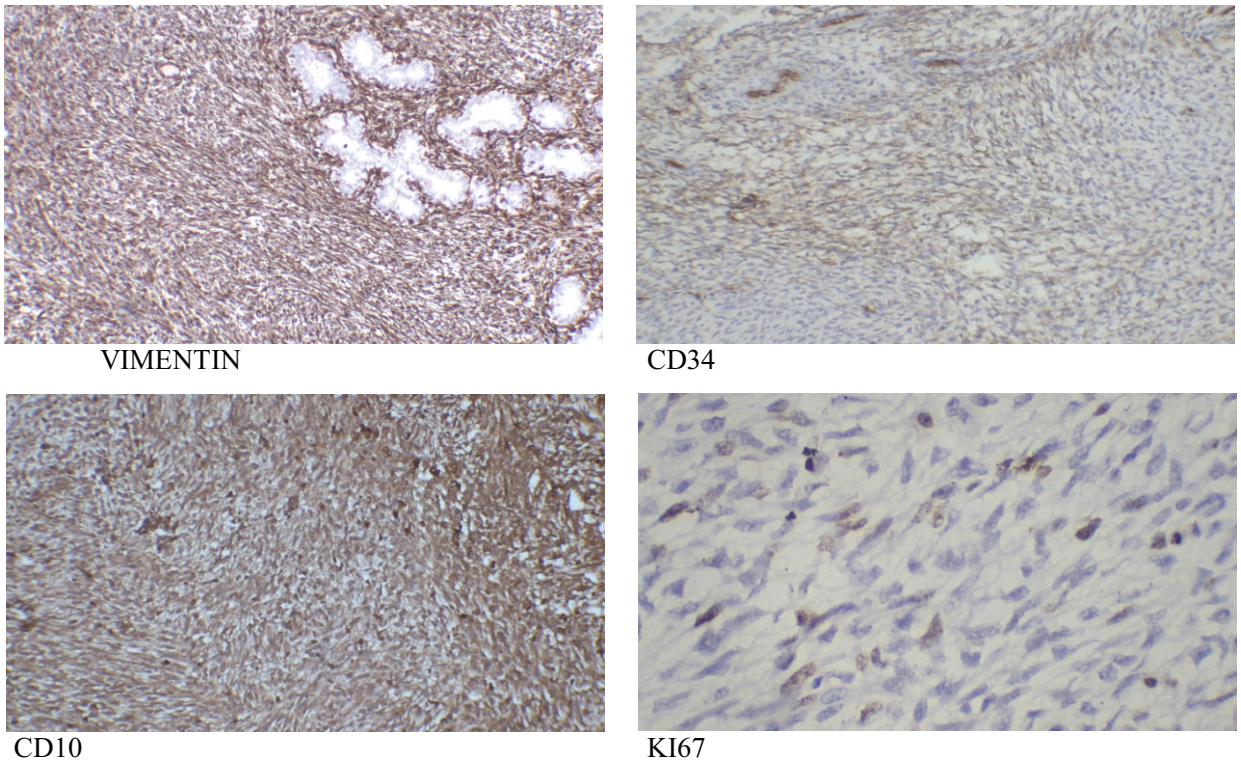

Figure 3 IHC - Tumour cells are positive for Vimentin, CD34 and CD10. Proliferative index Ki67is 20%
Acknowledgement: we Acknowledge Dr. Nidhi Chanchalani, Consultant Pathologist (precision path lab) for her inputs. We will be highly obliged.

REFERENCES:

1. Hassan S, Adari G. Primary Breast Sarcoma: case report. East Afr Med J 2004; 81(7):375-7.
2. Khuraijam B, Saxena P, Khurana N, Negi S. Periductal Stromal Sarcoma of the Breast with Coexistent Tuberculous Mastitis. J Midlife Health. 2017 Jul-Sep;8(3):142-4.
   doi: 10.4103/jmh.JMH_14_17. PMID: 28983162; PMCID: PMC5625579.
3. Lan Y, Zhu J., Liu J., Yang H., Jiang Y., Wei W. Periductal stromal sarcoma of the breast: A case report and review of the literature". Oncology Letters. 2014 Sep;8(3):1181-3.
4. Burga AM and Tavassoli FA: Periductal stromal tumor: a rare lesion with low-grade sarcomatous behavior. Am J Surg Pathol.2003; 27:343-8.
5. Powell CM and Rosen PP: Adipose differentiation in cysto- sarcoma phyllodes. A study of 14 cases. Am J Surg Pathol.1984 Jul;18(7):720-7.
6. Oberman HA, Nosanchuk JS and Finger JE: Periductal stromal tumors of breast with adipose metaplasia. Arch Surg.1969;98:384-7.
7. Callery CD, Rosen PP and Kinne DW: Sarcoma of the breast. A study of 32 patients with reappraisal of classification and therapy. Ann Surg 201: 1985 Apr;201(4):527-32.
8. Tavassoli FA and Devilee P (eds): World Health Classification of Tumours. Pathology and Genetics of Tumours of the Breast and Female Genital Organs. IARC Press, Lyon, 2003.
9. Rao AC, Geetha V, Khurana A: Periductal stromal sarcoma of breast with lipoblast-like cells: a case report with review of literature. Indian J Pathol Microbiol 2008, 51:252-4.
10. Fard EV, Zhang S. Periductal Stromal Tumor of the Breast: Case Report and Literature Review. Ann Clin Lab Sci. 2018 Nov;48(6):770-5. PMID: 30610048.
11. Askan G, Arıbal E, Ak G, Kaya H. Periductal Stromal Tumor of the Breast: A Case Report and Review of the Literature. *J Breast Health*. 2016; 12(3):133-6. doi:10.5152/tjbh.2016.2889